

---

**ABSTRACT**

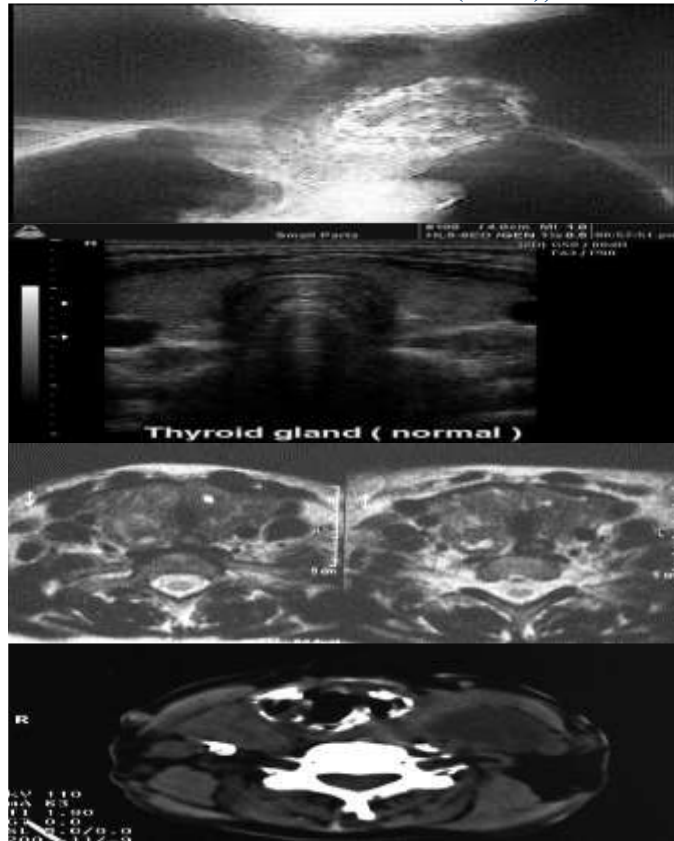
Thyroid gland is butterfly shaped organ which consists of two cone lobes and belongs to the endocrine system. It lies in front of the neck below the Adams apple. Thyroid disorders are some kind of abnormalities in thyroid gland which can give rise to nodules like hypothyroidism, hyperthyroidism, goiter, benign and malignant etc. Ultrasound (US) is one among the hugely used modality to detect the thyroid disorders because it has some benefits over other techniques like non-invasiveness, low cost, free of ionizing radiations etc. This paper provides a concise overview about segmentation of thyroid nodules and importance of neural networks comparative to other techniques.

**KEYWORDS:** (Thyroid, Contrast Enhancement, Active Contours, Ultrasound, Local-region based.).

---

**INTRODUCTION**

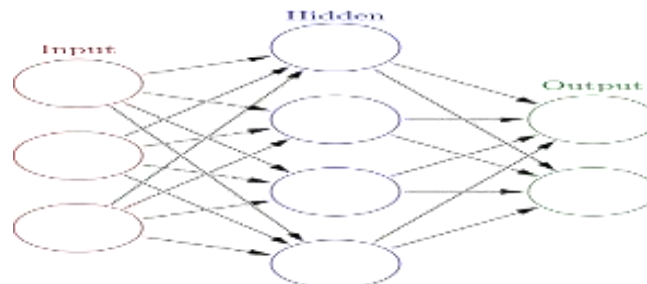
Image processing is one of the kind of signal processing in which an image or video is an input and output may be an image, video or set of parameters interconnected with that image. Any image can get taken according to our field or requirements. Image processing generally refers as digital image processing. Digital image processing involves computer algorithms to achieve processing over digital images. Medical imaging is one of the important areas of image processing, as manual diagnosis is more laborious and time consuming comparative to computerized techniques. With technology advancements, lots of techniques had originated to detect the various diseases associated with human body. Various imaging technologies are there like MRI (Magnetic Resonance Imaging), X-rays, CT (Computed Tomography), OCT (Optical Coherence Tomography) and US (Ultrasound). Thyroid gland belongs to endocrine system & consists of two cone lobes. It is butterfly shaped organ and lies just below the thyroid cartilage within in neck. It is helpful in controlling the secretion of hormones, metabolism as well as childhood growth and intelligence. Thyroid nodules are nothing but disorders in thyroid gland that may have adverse affect on human body. In addition to MRI and CT scans, US is one of the broadly used technique to detect the thyroid disorders because of its benefits like immediate response, short acquisition times, free of ionizing radiations, non-invasiveness and low cost comparative to other techniques. Thyroid nodules contain two main types i.e. benign and cancerous or malignant, except these hypothyroidism and hyperthyroidism are also the categories of thyroid disorders. Symptoms or signs of thyroid gland involve sudden increase in weight, unexplained weight loss, depression, constipation and infertility etc. As ultrasound images are best for clinical use in order to detect the thyroid nodule. But it has also a limitation that ultrasound images contain speckle noise in addition to grain noise.



*Figure:- Thyroid ultrasound image of a normal person.*

### THE NEURAL NETWORK

Segmentation plays an important role in medical analysis or in clinical use like lung detection, cancer detection, iris recognition, locating tumors, surgery planning and intra surgery navigation etc .Segmentation of medical imaging becomes a challenge due to poor quality of images. Except the medical field lots of other application of segmentation are machine vision, content based image retrieval, object detection, brake light detection and face detection etc. .Segmentation of thyroid nodule involves different steps depending upon particular segmentation method. Various segmentation methods are there like neural networks, edge detection, histogram methods, compression methods, clustering methods, region growing methods etc .



*Figure:- Neural Networks*

An artificial neural network is a group of interconnected nodes similar to the huge network of neurons in a brain. Each circular node represents an artificial neuron and an arrow represents a connection from the output of one neuron to the input of another neuron as shown below. Basically neural network has three layers i.e. input layer, hidden layer &

output layer. These layers communicate with one another over a large number of weighted connections. There is no single formal definition of artificial neural network. Though, a class of statistical models may commonly be called "Neural" if they consist of sets of adaptive weights & are capable of estimating non-linear functions. Adaptive weights are connection strengths between neurons, which get activated during prediction as well as training phase.

### PROPOSED METHODOLOGY(VECTOR MACHINE)

The basic steps of the proposed methodology are shown in Fig. below. The various stages of proposed technique are US database (obtained from Radiologist), image enhancement, feature extraction, segmentation using SVM

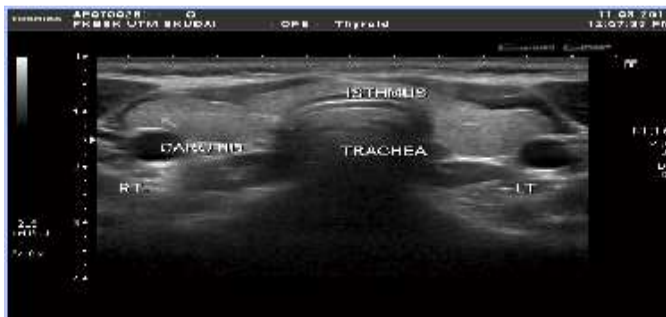Support vector machine- Support vector machine (SVM) are basically linear classifiers. SVM is widely accepted classifier, considered very effective for pattern recognition, machine learning and bioinformatics (protein classification and cancer classification). In SVM, a separator hyper plane between two classes is chosen to minimize the functional gap between two classes, the training data on the marginal sides of this optimal hyper plane called support vector. The kernel function is an important step is successful design of a SVM in specific classification task.

### METHODS AND PROCEDURES

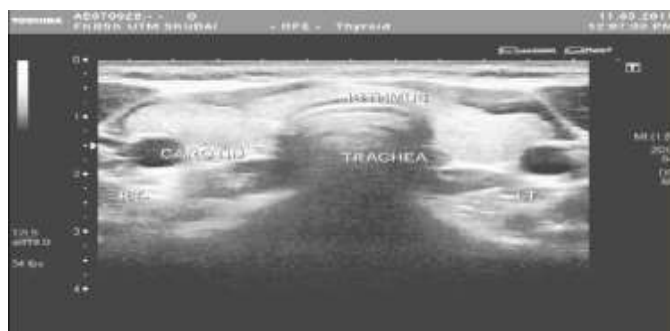Physicians often diagnosis the abnormal symptoms of the thyroid gland. Some of the US images of thyroid gland. Some of the US images of thyroid are shown in Fig. 2 the images used in this work are obtained from the website referred in. The images used are normal thyroid images.

#### Image processing method

Transverse view of thyroid ultrasound image will be used in this project. Therefore the measurement involves in this experiment just width (W), depth (D) and area of thyroid region. The ultrasound image is in RGB type which is an additive colour of red, green, and blue. The image is converted into gray scale image for further processing. Image processing toolbox provides image enhancement routines. The contrast enhancement of the image can be observed by applying histeq (enhance contrast using histogram equalization). The resulted image after histeq is show in Fig.



*Fig.- Original Thyroid image*



*Fig.- Thyroid image after histeq*

For the segmentation method, the thyroid region will be segmented into two sides that are right and left. For the right side of thyroid, the initialization mask is created suitable for the right thyroid region.

To minimize the weaknesses of this method, the automatic system that can give the width and length measurement of thyroid need to develop. By this system the error that occurs can be minimized. For further development of the system, the user friendly user interface need to been develop. This is because not all know how to use MATLAB especially doctor and radiologist. Therefore the user interface can help them to use the system.

### B. Image Enhancement

In thyroid US images, low visual quality greatly affects the segmentation and the volume estimation results. A pre-processing step is thus required to enhance and locate the probable thyroid region. The steps for image enhancement are Locating the probable thyroid region using horizontal projection Applying an Adaptive Weighted Median Filter (AWMF) to reduce speckles Applying two morphological operations, opening and closing to enhance the filtering result by removing the redundancy enhanced by the filter Compensating for different US images according to the intensity template of the thyroid region.

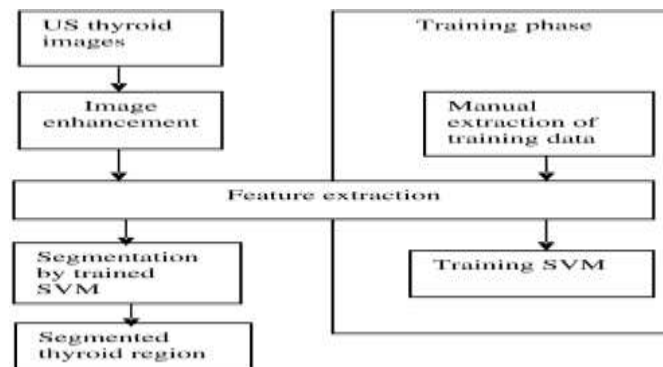


Figure 1: Proposed Methodology

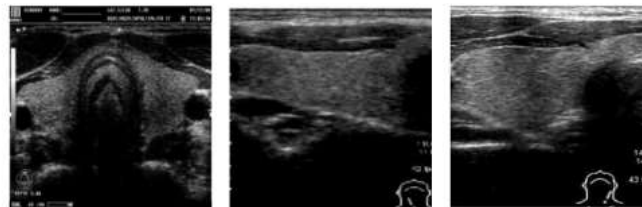

Figure 2: Ultrasound Images of Thyroid Gland

First, thyroid US image is taken. Image processing step includes removal of noise using filters and to enhance the image. Image segmentation is the process of partitioning an image into multiple segment or set of pixels used to locate object and boundaries. Each of the pixels in a region is similar with respect to some characteristics such as colour, intensity or texture. Image classification of thyroid nodule is done in order to eliminate operator dependency and to improve the diagnostic accuracy. Image classification using neural networks is done by texture feature extraction and then applying the back propagation algorithm.

#### (1) Locating Probable thyroid Region

In a thyroid US image, the thyroid gland is always in the middle, below the bright part and above the dark part of the image. Two reference values (R1 and R2) are defined to locate the probable thyroid region. The horizontal and vertical histograms are used to Determine these reference values. Here horizontal projection histogram is used to determine the two reference values. R1 is the row index with the largest average intensity in the horizontal projection of the US image. R2 is the first row index with an average Intensity of zero from the top to bottom in the horizontal projection of the US image. The probable thyroid region is located between the row and the row of the US thyroid image.

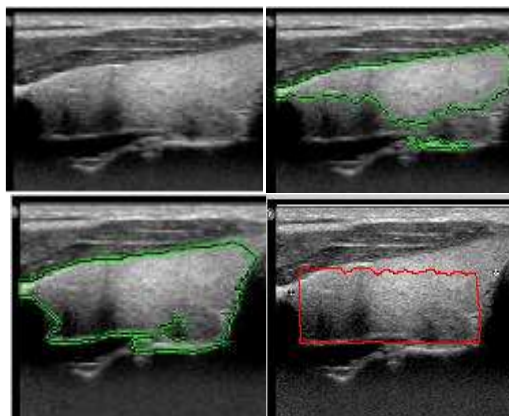
**Algorithm used:-** Active Contour without Edges (ACWE) proposed by Chan Vese, is a region based method. It tends to separate the image into two homogeneous regions according to a mean value. Active Contour without Edges is

sensitive to initialization. The initial curve can be anywhere in the image, and the interior contours are automatically detected. Active Contour without Edges detects objects whose boundaries are not necessarily defined by gradient or smooth boundaries. In this section, the results of implementing the above discussed algorithm have been presented and compared. The algorithms were first implemented on Scintigraphy Images and then on ultrasound Images. The presented algorithms were implemented in MATLAB R2008b version.

### 3.1 Scintigraphy Images

The Scintigraphy images were collected from various web sources. Three algorithms namely Active Contour without edges; Localized region Based active contour and Distance Regularized Level Set were implemented on Scintigraphy images. The algorithms were compared in terms of time and no of iterations taken by them to segment the image. The results of scintigraphy images are shown in fig. 1. Fig 1(a) shows the thyroid scintigraphy original image (b) shows the segmented image after applying ACWE (c) shows the image after applying LRAC and (d) shows the segmented image after applying DRLSE. It is evident from the images that the results of Localized region based Active contour are better than the other algorithms. A comparison of these segmentation algorithms have been shown in fig. 3 in terms of time and no of iterations. Following table shows the corresponding values for the graph.

	← Scintigraphy	Images →	
	ACWE	LRAC	DRLSE
No. of iterations	280	170	411
Time(Sec)	3.9	2.10	46



**Fig:-(a) Thyroid US original image (b) results after ACWE (c) LRAC (d) DRLSE**

Fig. (a) Shows the thyroid US original image (b) shows the segmented image after applying ACWE and (c) shows the segmented result after applying LRAC and (d) shows the segmented result after DRLSE. Localized region based active contour method segments the image better than the ACWE and DRLSE. Comparison has been made on the basis of Precision factor which. The algorithms were implemented on a dataset of 10 Scintigraphy images. Precision values were calculated for these 10 Scintigraphy images. Precision percentage for ACWE is 57% and for LRAC is 80 %.

### CONCLUSION

To inspect the abnormalities in thyroid gland various imaging modalities are used. In this paper, two thyroid imaging modalities were discussed: Ultrasound Imaging and Scintigraphy. Segmentation algorithms were implemented on both the imaging modalities. Furthermore, the segmentation algorithms were compared based on several parameters

in both the imaging modalities. The best image segmentation algorithm was Localized Region Based as it took less time and less number of iterations in Scintigraphy images. This algorithm had a precision of 80% in segmenting the US images. In future work, comparison of more segmentation algorithms could be implemented on thyroid images.

## REFERENCES

- [1] R.Maj AHultén, Suketu DP., M. Westgren, N.Papadogiannakis, AnnaM.J., JonJ. N and Erik I., "On the paternal origin of trisomy 21 Down syndrome", *Molecular Cytogenetics*, Volume 3: 4, 2010
- [2] Peter C. Tay, C.D.G., John A. Hossack, *Ultrasound Despeckling for Contrast Enhancement*. IEEE Transactions on Image Processing, 2010. 19(no. 7).
- [3] Frederic L, L., Ernest J. Feleppa, *Image Processing and Pre-Processing for Medical Ultrasound*. IEEE, 2000.
- [4] Soong-Der Chen, A.R.R., *Contrast Enhancement using Recursive Mean-Separate Histogram Equalization for Scalable Brightness Preservation*. 2003.
- [5] Shawn Lankton, A.T., *Localizing Region-Based Active Contours*. IEEE Transaction on Image Processing, 2008. 17(11).
- [6] Eddy C.K. Tong, S.R., *Scan Measurement of Normal Enlarged Thyroid Glands*. 1972.
- [7] M. Savelonas, D.M., D. Iakovidia, S.Karkania, *A Variable Background Active Contour Model for Automatic Detection of Thyroid Nodule in Ultrasound Images*. IEEE, 2005.
- [8] M. Savelonas, D.M., D. Iakovidia, S.Karkania, *A Variable Background Active Contour Model for Automatic Detection of Thyroid Nodule in Ultrasound Images*. IEEE, 2005.
- [9] H. Jack Baskin, D.S.D., Robert A. Levine, *Thyroid Ultrasound and Ultrasound-Guided FNA* second edition. 2008, NY, USA: Springer. 253.
- [10] Vivien Bonert, T.C.F., *The Thyroid Gland*. 2003. p. 593-602.
- [11] Nananda F. Col, M.I.S., Gilbert H. Daniela, *Subclinical Thyroid Disease*. *Journal American Medical Associations (JAMA)*, 2004. 291(2).
- [12] Muhammad Luqman Muhd Zain, I.E., Mumtaj Begum, *Enhancement of Bone Fracture Image Using Filtering Techniques*. *The International Journal of Video and Image Processing and Network Security*. 9(10).
- [13] Sheeja Agustin A and S. Suresh Babu, "A Review of Thyroid Disorder Detection, Segmentation and Classification on Medical Images," *International Journal of Engineering and Advanced Technology (IJEAT)* ISSN, no. 32, pp. 2249 – 8958, 2013.
- [14] Chuan-Yu, Yue-Fong Lei, Chin-Hsiao Tseng, and Shyang-Rong Shih. Chang, "Thyroid segmentation and volume estimation in ultrasound images," *Biomedical Engineering*, IEEE Transactions on 57, no. 6 , pp. 1348-1357, 2010.
- [15] Hitesh, and Alka Jindal Garg, "Segmentation of thyroid gland in ultrasound image using neural network," in *In 2013 Fourth International Conference on Computing, Communications and Networking Technologies (ICCCNT)*, 2013, pp. 1-5.
- [16] B., and B. R. Gupta Gopinath, "Majority voting based classification of thyroid carcinoma," in *Procedia Computer Science* 2 , 2010, pp. 265-271.
- [17] "<http://www.mdhil.com/thyroid-signs-symptoms/>".
- [18] "[http://en.wikipedia.org/wiki/Thyroid\\_nodule](http://en.wikipedia.org/wiki/Thyroid_nodule)".
- [19] "[http://en.wikipedia.org/wiki/Noise\\_reduction](http://en.wikipedia.org/wiki/Noise_reduction)".
- [20] Debdoot, Hrushikesh Garud, Amit Suveer, Manjunatha Mahadevappa, and Jyotirmoy Chatterjee Sheet, "Brightness preserving dynamic fuzzy histogram equalization," *Consumer Electronics*, IEEE Transactions on 56, no. 4 , pp. 2475-2480, 2010.
- [21] "<http://www.medison.ru/uzi/img/p139.jpg>".